

# IPS EMPRESS<sup>®</sup> 2

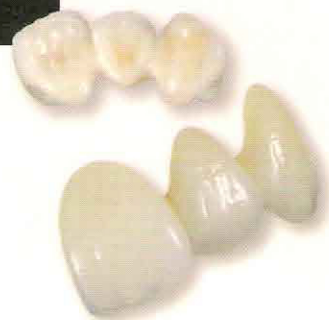Your Bridge 2 The Esthetic Revolution.<sup>SM</sup>

## Anterior Chairside Preparation Guide

FOR IPS EMPRESS<sup>®</sup> AND IPS EMPRESS<sup>®</sup>2 RESTORATIONS

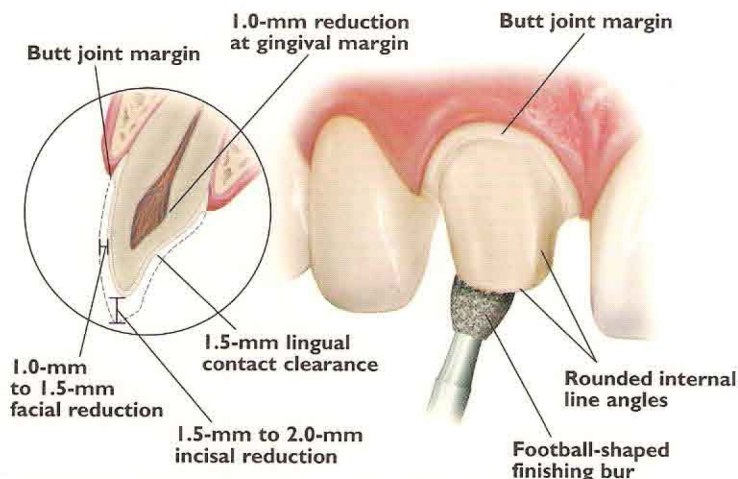
		IPS Empress <sup>®</sup>	IPS Empress <sup>®</sup> 2	Targis <sup>®</sup> /Vectris <sup>®</sup>
Anterior	Crown	X	X	
	Veneer	X		
	Bridge		X	
Posterior	Crown		X	X
	Bridge		X†	X
	Inlay/Onlay	X		X

†One pontic and the second premolar as the most distal abutment.



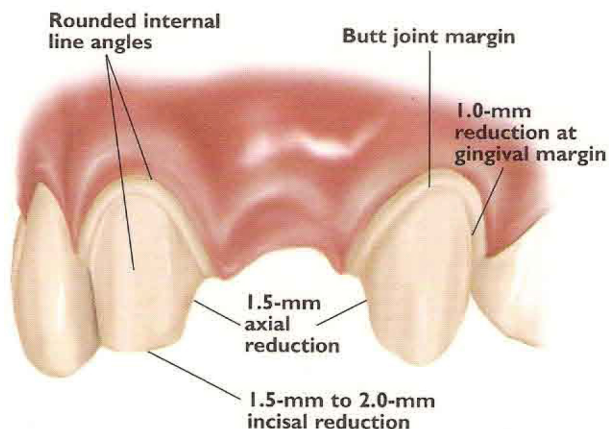
### Full-Coverage Restorations

#### ANTERIOR CROWN PREPARATION



### 3-Unit Bridge Restorations

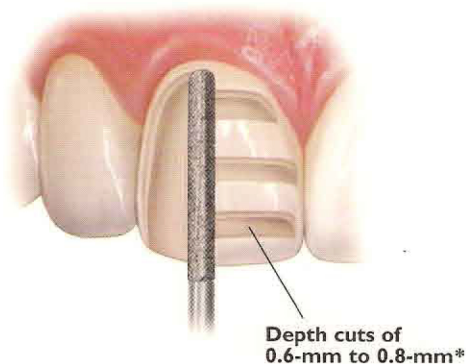
#### 3-UNIT BRIDGE PREPARATION



### Veneers (IPS Empress<sup>®</sup> Staining Technique)

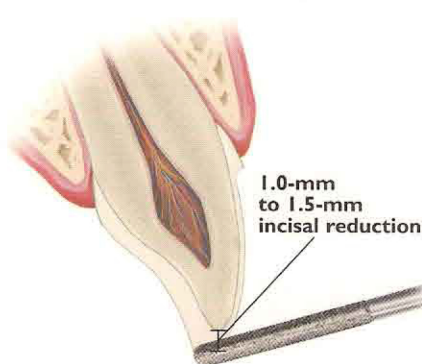
#### UNIFORM FACIAL PREPARATION

A medium grit, round-ended, diamond bur is used to remove a uniform thickness of facial enamel by joining the depth-cut grooves.



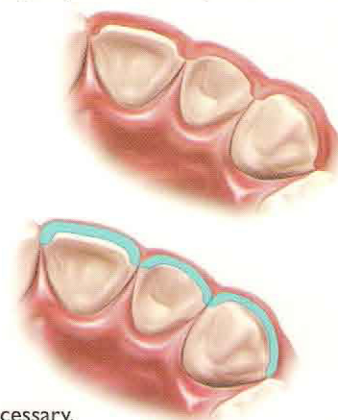
#### INCISAL PREPARATION

The diamond bur is angled to bevel back the incisal edge.



#### CHAMFER MARGINS

Correct preparation of the chamfer margins interproximally allows the appropriate bulk of porcelain.

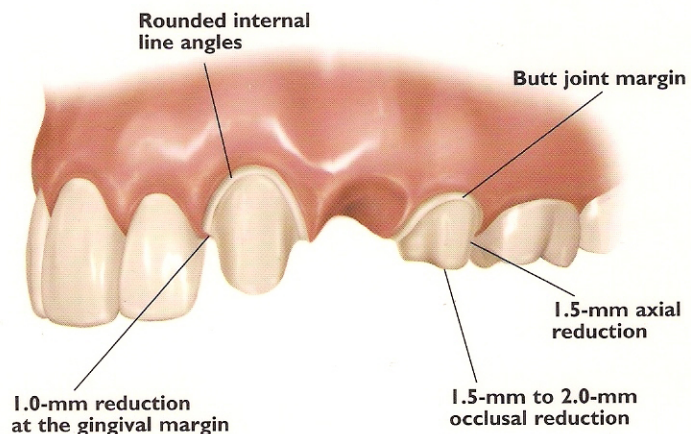
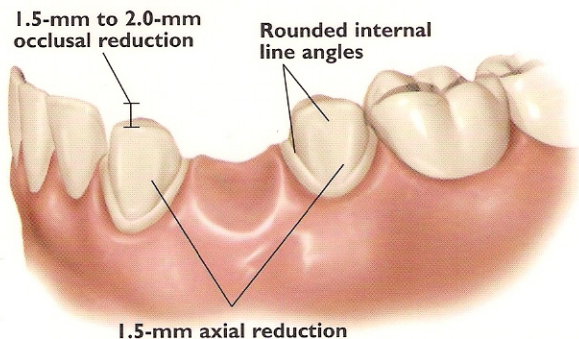


\*Please note: For additional masking capabilities and/or layering techniques, further reduction may be necessary. Contact your laboratory for further information.



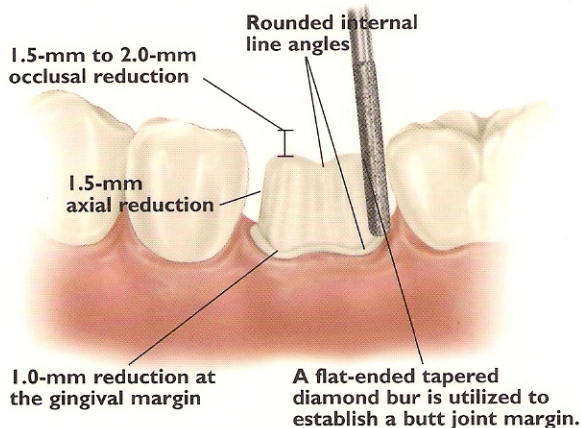
## 3-Unit Bridge Restorations

### 3-UNIT BRIDGE PREPARATION

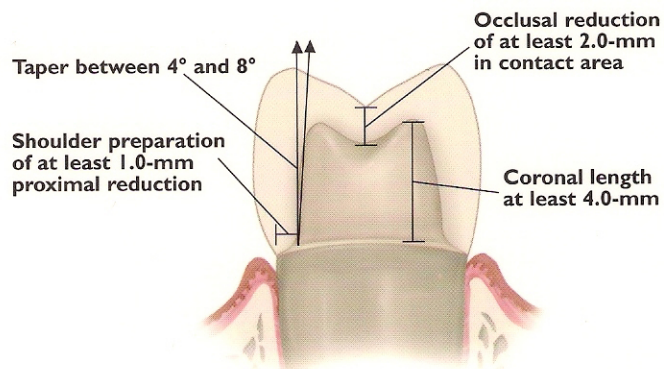


## Full-Coverage Restorations

### POSTERIOR CROWN PREPARATION

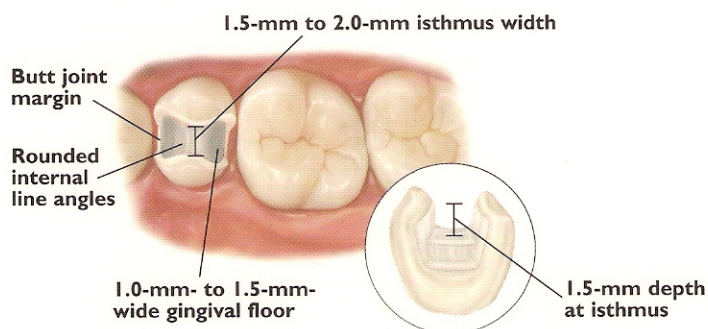


### CONVENTIONAL CEMENTATION PREPARATION



## Inlays/Onlays

### INLAY PREPARATION



### ONLAY PREPARATION

